

## PennHIP Report

Referring Veterinarian: Dr Leland Davis Email: lelanddavis@att.net	Clinic Name: Reelfoot Animal Hospital Clinic Address: 402 W Reelfoot Avenue Union City, TN 38261 Phone: (731) 885-1943 Fax: (731) 885-1423
---	--

## Patient Information

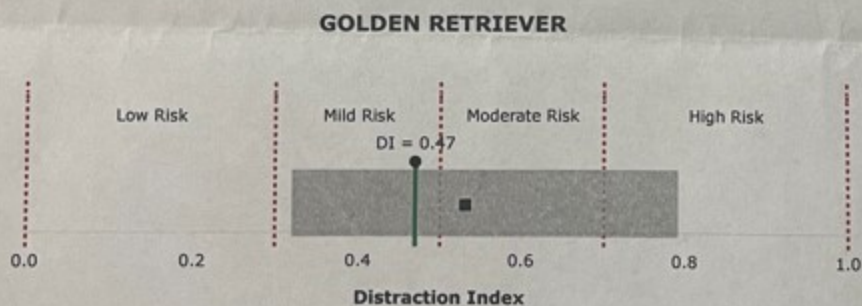
Client: Barlow, Scottie	Tattoo Num:
Patient Name: Rosings the Bright of the Hamptons	Patient ID: 122161
Reg. Name: Rosings the Bright of the Hamptons	Registration Num: 5532401708
PennHIP Num: 183014	Microchip Num: 98102847880429
Species: Canine	Breed: GOLDEN RETRIEVER
Date of Birth: 14 Feb 2022	Age: 10 months
Sex: Female	Weight: 61.8 lbs/28 kgs
Date of Study: 19 Dec 2022	Date Submitted: 20 Dec 2022
Date of Report: 22 Dec 2022	

## Findings

Distraction Index (DI): Right DI = 0.47, Left DI = 0.42.
Osteoarthritis (OA): No radiographic evidence of OA for either hip.
Cavitation/Other Findings: No cavitation present.

## Interpretation

Distraction Index (DI): The laxity ranking is based on the hip with the greater laxity (larger DI). In this case the DI used is 0.47.  
 OA Risk Category: The DI is between 0.31 and 0.49. This patient is at mild risk for hip OA.  
 Distraction Index Chart:



**BREED STATISTICS:** This interpretation is based on a cross-section of 25074 canine patients of the GOLDEN RETRIEVER breed in the AIS PennHIP database. The gray strip represents the central 90% range of DIs (0.32 - 0.79) for the breed. The breed average DI is 0.53 (solid square). The patient DI is the solid circle (0.47).

**SUMMARY:** The degree of laxity (DI = 0.47) falls within the central 90% range of DIs for the breed. This amount of hip laxity places the hip at a mild risk to develop hip OA. No radiographic evidence of OA for either hip.